

## COMPARISON OF SCIATIC NERVE COURSE IN AMPHIBIANS, REPTILES AND MAMMALS

SOBIA MALIK<sup>1</sup>, SADAF AHMED<sup>1&2</sup>, M.A.AZEEM, SHAMOON NOUSHAD<sup>2</sup>  
AND SIKANDER KHAN SHERWANI<sup>2&3</sup>

<sup>1</sup>*Department of Physiology, University of Karachi, Karachi, Pakistan*

<sup>2</sup>*Advance Educational Institute and Research Center, Karachi, Pakistan*

<sup>3</sup>*Department of Microbiology, Federal Urdu University of Arts, Science and Technology, Karachi, Pakistan*

### Abstract

The sciatic nerve is the longest single nerve in the body arising from the lower part of the sacral plexus; the sciatic nerve enters the gluteal region by the greater sciatic foramen of the hip bone. It continues down the posterior compartment of the thigh, until it separates into the tibial nerve and the common peroneal nerve. The location of this division varies between individuals. Various techniques were used for the study of the sciatic nerve anatomy that are able to depict the sciatic nerves division. The purpose of this study is to compare sciatic nerve anatomy, its branches to different muscles in amphibian (Frog), reptiles (Uromastix) and mammals (Rabbit) and how these morphometric characteristics vary in these animals. The dissection was done to identify the location and branches of sciatic nerve from both the right and left side taken from adult & both sexes of Frog, Uromastix and Rabbit and photographs had been taken to understand comparative anatomy of sciatic nerve in these animals. The sciatic nerve course observed after dissection was different among these animals with respect to its branching to different muscles and diameter. The location of formation and division of sciatic nerve vary from animal to animal. This variance is due to difference in number of spinal nerves. In frog, there are ten spinal nerves (nine in *Rana tigrina*); in Uromastix, sixteen spinal nerves; while in Rabbit thirty-seven spinal nerves have been observed. Sciatic nerve thickness also varied among these animals. There is a clear difference in the course of sciatic nerve among these three animals, it is definitely on the basis of their branches and difference in diameter innervating both slow and fast muscle fiber types indicate major differences in locomotory pattern.

### Introduction

Sciatic nerve is one of the longest nerves in the body that arises from the lower part of sacral plexus, enters the gluteal region by the greater sciatic foramen of the hip bone. It continues down the posterior compartment of the thigh, until it separates into the tibial nerve and the common peroneal nerve (Mark, 1990; Lord, 1991; Raymond and Victor, 1993 & Helen and Montgomery, 1996). Handheld ultrasound in adults used for the anatomy of the sciatic nerve and its division into the tibial and peroneal part. Handheld ultrasound is able to depict the sciatic nerves division (Schwemmer *et al.*, 2005). Magnetic stimulation also helps in studying neuronal morphology of the frog sciatic nerve (Rotem and Moses, 2006) and it was found that nerves has branches, which runs down the leg by giving branches to its muscle. Small branches from the sciatic plexus are also given to the large intestine, urinary bladder and cloaca (Dvidyarthi, 1979). Akita (1992) dissected five pelvic halves from three male iguanas (Iguanidae Iguana iguana) and two pelvic halves from one male varanus (Varanidae *Varanus dumerillii*), in order to obtain detailed data on the relationship of the lumbosacral plexus and the muscles of the pelvic outlet. According to the positions of the passage of the metazonal nerves, the nerves can be divided into three groups: 1) the nerves passing dorsal to the caudofemoralis muscle, 2) the nerves passing between the caudofemoralis and the caudoischadicus major, 3) the nerves passing ventral to the caudoischadicus major. In consideration of the sites of origin from the lumbosacral plexus, a stratificational analysis can be proposed; group 1 arise craniodorsal to group 2, and group 3 caudoventral to group 2. It is suggested that the pelvic outlet muscles (caudofemoralis, quadratus caudae, obliquus cloacae, transversus cloacae profundus, retractor penis, caudoischadicus major, and the caudoischadicus minor) are derived from the ventral muscles of the posterior limb, and have moved caudally concomitant with the caudal migration of the cloaca. In rabbit the sciatic nerve is visible near the piriformis muscle, as it passes through the sciatic notch. This large nerve innervates the muscles found in the posterior region of the thigh and originates from the seventh lumbar and first sacral nerves (Popesco *et al.*, 1992). Germana *et al.*, (1992) observed that in the rabbit the myelinated fibres with the largest diameter originating from the sciatic nerve distribute mainly into the peroneal nerve. The distribution of the myelinated fibre diameters is unimodal in the sciatic nerve, but bimodal both in the peroneal and tibial nerves. The quotient axon diameter/fiber diameter (g ratio) shows a different trend between the sciatic nerve and the branches originating from it. Except for the peroneal nerve, the increase of the axon calibre corresponds to the reduction of the relative myelin sheath thickness and therefore to the reduction of internodal distance. The results show that the sciatic nerve and its terminal branches in the rabbit

have morphometrical characteristics that are peculiar and differ from those of the other rodents (Swett *et al*, 1991).

### Materials and Methods

**Animals:** 8 adult Frogs (*Rana esculanta*) of fresh-water or near water in damp places on land were used. 9 *Uromastix* that lives in dry, soft, sandy tracts with scant vegetation in burrows and 8 adult rabbits (*Oryctolagus cuniculus*) lives in fields, grass-lands and open wood-lands and in burrows underground were selected. All three animals of both sexes were selected for both right and left nerves for dissection.

**Solutions:** All the chemicals used in the preparation of following solutions were obtained from E. Merck, Germany or Anala-R:

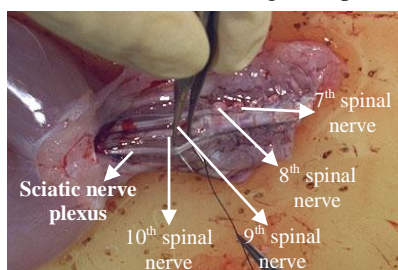
- i. For the experiments on *Uromastix hardwickii*, similar composition of reptilian buffer was used as described by Khalil & Masseih (1954)
- ii. For experiments on Frog, Ringer's solution (Franhenhauser *et al.*, 1965)
- iii. For Rabbit, Kreb's solution (Winegrad and Shanes, 1962) was used.

### Nerve dissection procedure:

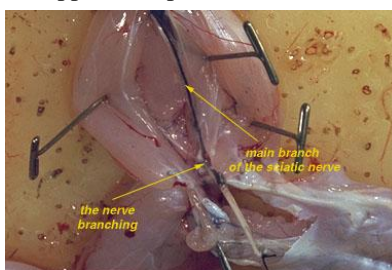
- 1) After removing the skin from the legs and abdomen of the double-pithed frog (decapitated uromastix and rabbit). For which, a cut has been put around the abdomen, and peeled the skin downward and off the animal.
- 2) The animal has been continuously moisted at all times with frog Ringer's solution (reptilian for uromastix & kreb for rabbit)
- 3) The urostyle has been grasped with forceps and has been cut freely; this would be able to observe the nerve plexus below it.
- 4) Using a forcep, the sciatic nerve has been located and lifted free from the associated fascia and the sciatic artery. Blunt dissection techniques were required
- 5) The nerve has been cut from the spinal cord
- 6) A piece of thread has been tied around the free end of the nerve so that it could be handled gently.
- 7) Using forceps, the procedure has been continued to expose the nerve from the animal till the insertion in gastrocnemius muscle.

### Results

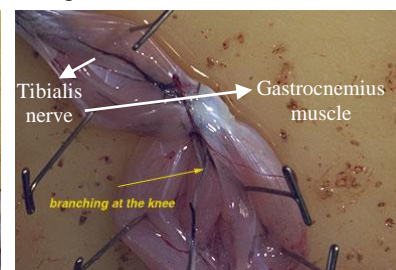
The tibialis nerve give branches to gastrocnemius, tibialis postieus and numerous muscles of the planter surface of the foot in frog. The peroneus supplies the peroneus muscle tibialis (Fig. 1.3).



**Fig. 1.1**

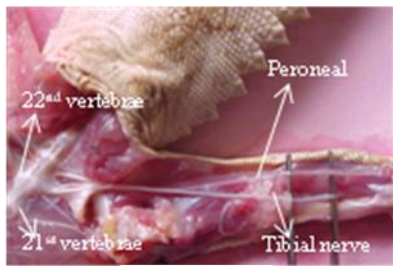


**Fig. 1.2**

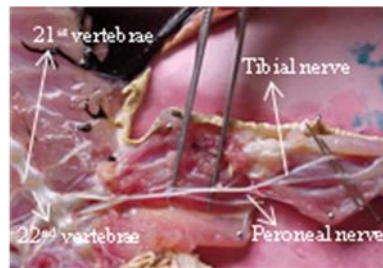


**Fig. 1.3**

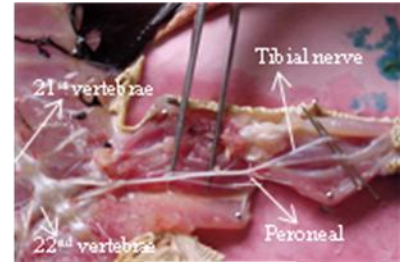
**Fig. 1.** Frog: The 7<sup>th</sup>, 8<sup>th</sup>, 9<sup>th</sup> spinal nerves pass almost directly backward and are closely associated and anastomose to form the lumbo-sacral or sciatic plexus from which several nerves arise going to the hind limb (Figure 1.1). The most important nerve is sciatic nerve, coming from 8<sup>th</sup> and 9<sup>th</sup> vertebrae, two separate nerve branches unite and form the thicker sciatic nerve and dividing into two main branches at knee joint, namely tibialis and peroneus (Fig. 1.1, 1.2, 1.3).



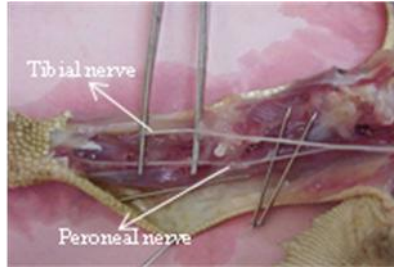
**Fig. 2.1**



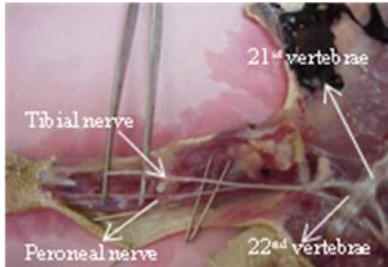
**Fig. 2.2**



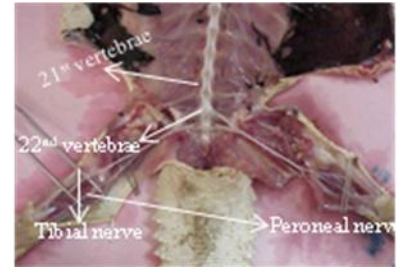
**Fig. 2.3**



**Fig. 2.4**



**Fig. 2.5**

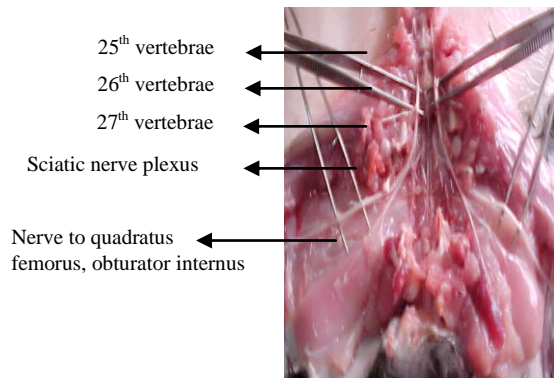


**Fig. 2.6**

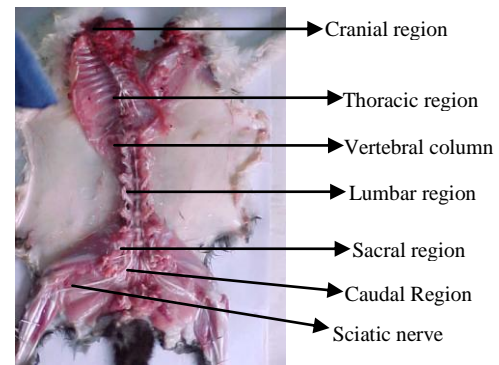
**Fig. 2. Uromastix:** Many muscles receive multiple innervations. The more posterior nerve roots give rise to the obturator nerve to the ventral pelvic muscles, and the Ichiadicus nerve, which runs to the muscles of the ilium and then divides to form the peroneal and sciatic nerves (Fig. 2.1).

In *Uromastix* the anterior two nerve roots interconnect provide major innervations (via crural, femoral, and tibial nerves) to the inguinal muscles, thigh adductors, and leg extensors (Figure 2.1-2.6).

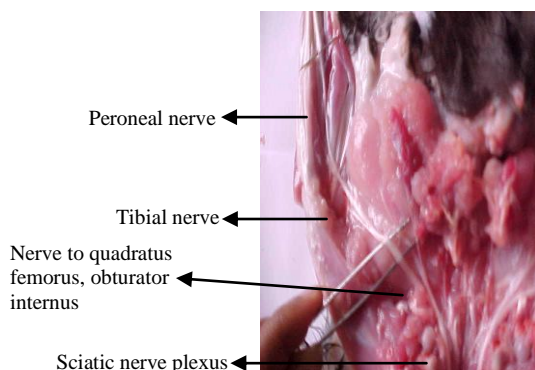
There are also sacral branches going to the bladder. Sacral nerves are presumed to innervate the genitalia. In *uromastix*, arising from 20<sup>th</sup> and 21<sup>st</sup> vertebrae, two separate branches unite and form sciatic nerve connecting the spinal cord with limb (Fig. 2.1-2.3, 2.5-2.6).



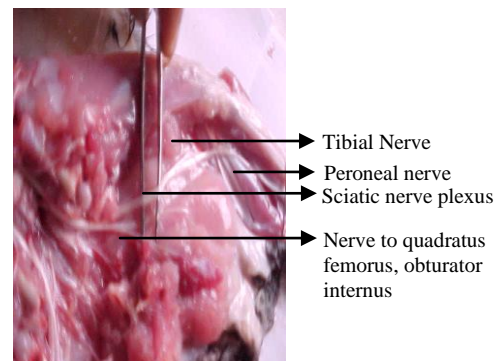
**Fig. 3.1**



**Fig. 3.2**



**Fig. 3.3**



**Fig. 3.4**

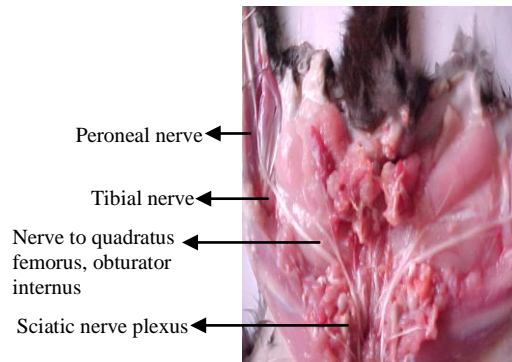


Fig. 3.5

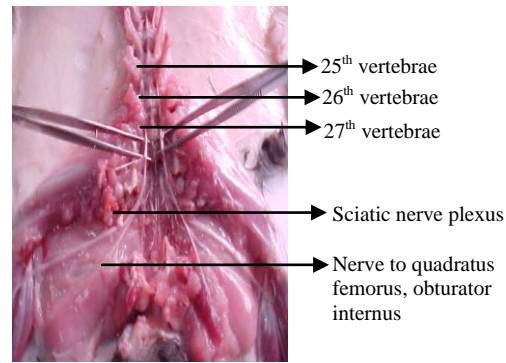


Fig. 3.6

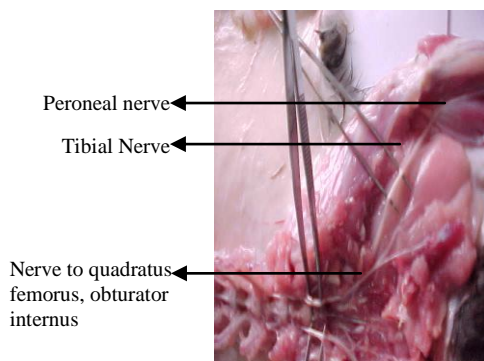


Fig. 3.7

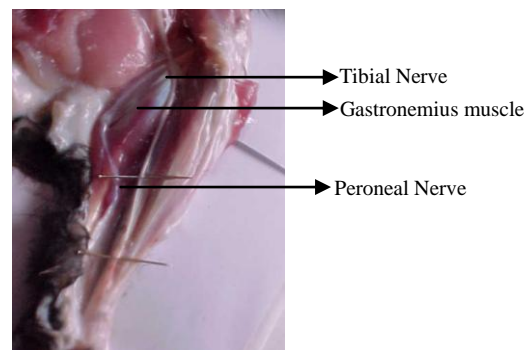


Fig. 3.8

**Fig. 3. Rabbit Sciatic Nerve:** The 4-7 lumbar nerve and 1-3 sacral nerves unite to form sacral plexus or lumbosacral plexus (Figure 3.2). The main branches of this plexus are femoral, obturator and sciatic nerve supplying to the muscle and skin of the hind limb (Figure 3.1, 3.3-3.7).

Arising from 25<sup>th</sup>, 26<sup>th</sup>, 27<sup>th</sup>, 28<sup>th</sup> vertebrae, different spinal nerves are formed, which innervate lower region of the body in rabbit (Figure 3.1, 3.5, 3.6). Arising from 27<sup>th</sup> and 28<sup>th</sup> vertebrae, these two spinal nerve form sciatic nerve which gives out different branches further to innervate the thigh and leg region (Figure 3.1, 3.5, 3.6). It passes through sciatic notch and become visible near piriform muscles. This large nerve innervates the muscles found in the posterior region of the thigh and originates from the seventh lumbar and first sacral nerves (Figure 3.2). Sciatic nerve runs down and gives branches to gluteal muscles. Further sciatic nerve innervating the semitendinosus and semimembranosus; branches at knee and two main branches, tibial and peroneal nerve are formed. The tibial nerve innervates gastrocnemius muscle, soleus, tibialis posterior, flexor digitorum longus, and flexor hallucis longus muscle (Figure 3.8, 3.3-3.5, 3.7).

Branches of tibial nerve in foot are medial plantar and lateral plantar nerves. Peroneal nerve divides into superficial nerve innervating to peroneus longus and peroneus brevis muscle and deep peroneal nerve innervating tibialis anterior, extensor hallucis longus, peroneus tertius and extensor digitorum longus and brevis muscle (Figure 3.8, 3.3-3.5, 3.7). Laterally sciatic nerve gives branches to semimembranosus. Medially and superficially it innervates biceps femoris (Figure 3.8, 3.3-3.7). 4<sup>th</sup> sacral nerve supplies to the skin and muscle of sacral region. The caudal nerve supply to the tail region (Figure 3.2).

## Discussion

In the present study three animals that belong to three different classes of animal have been worked out for two things, Firstly identification of the exact course of sciatic nerve and differences in it in the frog, uromastix and rabbit and secondly measurement of nerve conduction velocity from isolated right and left sciatic nerves of frog, uromastix and rabbit. It was found that sciatic nerve anatomy, its branches to different muscles in amphibian, reptiles, and in mammals can easily be compared in view of our results. The location of formation and division of sciatic nerve vary from animal to animal. This variance is due to difference in number of spinal nerves. In human there are thirty-one spinal nerves (Gerard *et al.*, 1992; Mark, 1990; Lord, 1991; Raymond and Victor, 1993 & Helen and Montgomery, 1996). Whereas in Frog, there are ten spinal nerve (nine in *Rana tigrina*); in Uromastix sixteen spinal nerves; in Rabbit thirty-seven spinal nerve (Jordan and Verma, 1997a, b, c). In squirrel and rabbit, there are about 40 pairs of spinal nerves, one pair to each vertebra except in the caudal

region, thus, there are 8 cervical, 13 thoracic, 6 or 7 lumbar, 3 to 4 sacral and several pairs of caudal nerves (Jordan and Verma, 1997d).

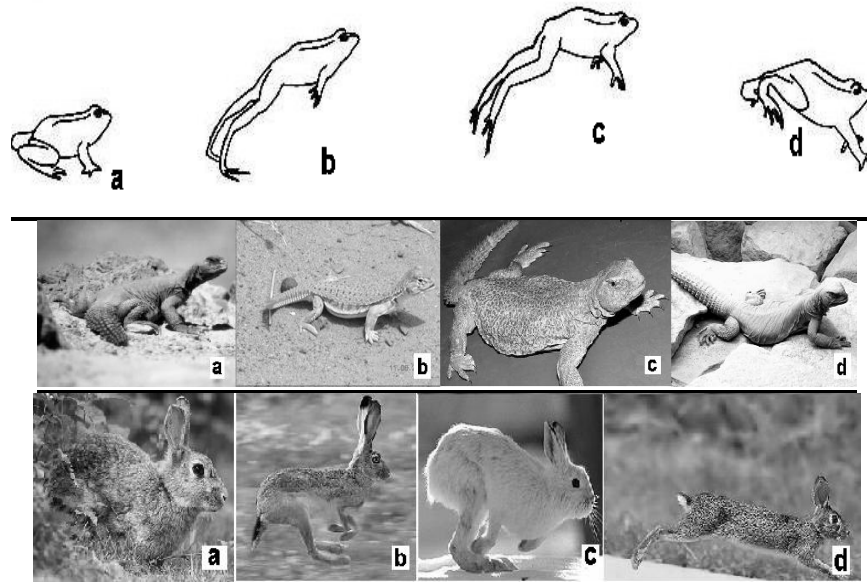
A number of variations in the course and distribution of the sciatic nerve have been reported. Bifurcation into its two major divisions (common peroneal and tibial) may occur anywhere between the sacral plexus and the lower part of the thigh. The two terminal branches of the sciatic may arise directly from the sacral plexus (Bergman *et al.*, 1988). In humans sacral plexus is formed by the combination of the fourth and fifth lumbar nerves and the first four nerves in the sacral spine. Sciatic nerve is formed on the right and left hand side of the lower spine by the combination of the fourth and fifth lumbar nerves and the first three nerves in the sacral spine (Gerard *et al.*, 1992). In Frog, sacral or sciatic plexus is formed by the combination of the seventh, eighth and ninth spinal nerves. Sciatic nerve is formed by 8<sup>th</sup> and 9<sup>th</sup> spinal nerve. 10<sup>th</sup> spinal nerve, which is absent in *Rana tigrina*, also joins sciatic nerve. (Dvidyarthi, 1979). In *Uromastix*, sacral plexus arises as four to six branches from spinal nerves associated with the last trunk vertebra and sacral vertebrae. Sciatic nerve arises from 20<sup>th</sup> and 21<sup>st</sup> vertebrae. In Rabbit sacral plexus or lumbosacral plexus arises from fourth to seventh 4-7 lumbar nerve and first three 1-3 sacral nerves. Sciatic nerve arises from the seventh lumbar and first sacral nerves (Dvidyarthi, 1979). Similarly in the carnivore the lumbosacral plexus, which innervates the pelvic limb and pelvis, is formed by ventral braches of spinal nerves L4 to S3. The lumbar portion of the plexus is located inside sublumbar musculature. In human, actually two nerves tibial and common peroneal bound together by common sheath of connective tissues. It splits into its division, usually at knee. As sciatic nerve descends through thigh, it sends branches to hamstring muscles (biceps femoris, Semitendinosus, Semimembranosus) and adductor magnus (Gerard *et al.*, 1992; Mark 1990; Helen *et al.*, 1996). Tibial nerve formed by the combination of the fourth and fifth lumbar nerves and the first three nerves in the sacral spine. Tibial nerve innervates gastrocnemius, plantaris, soleus, popliteus, tibialis posterior, flexor digitorum longus, and flexor hallucis longus muscle. Branches of tibial nerve in foot are medial plantar and lateral plantar nerves. Medial plantar nerve innervates to abductor hallucis, flexor digitorum brevis, and flexor hallucis brevis muscle (Gerard *et al.*, 1992; Mark 1990; Helen *et al.*, 1996). Peroneal nerve is formed by the combination of the fourth and fifth lumbar nerves and the first two nerves in the sacral spine. Peroneal nerve divides into superficial nerve innervating to peroneus longus and peroneus brevis muscle and deep peroneal nerve innervating tibialis anterior, extensor hallucis longus, peroneus tertius and extensor digitorum longus and brevis muscle (Gerard *et al.*, 1992; Mark, 1990 & Helen *et al.*, 1996).

In Frog, which is example of amphibians, the 7<sup>th</sup> spinal nerve leave the neural canal between 7<sup>th</sup> and 8<sup>th</sup> nerve, 8<sup>th</sup> nerve between 8<sup>th</sup> and 9<sup>th</sup> and 9<sup>th</sup> nerve between 9<sup>th</sup> and 10<sup>th</sup> vertebrae (Figure 1.1). Coming from 8<sup>th</sup> and 9<sup>th</sup> vertebrae, two separate nerve branches unite and form the thicker sciatic nerve innervating rectus anticus femoris, vastus externus, semi membranosus and dividing into two main branches at knee joint, namely tibialis and peroneus (Figure 1.2, 1.3). Eighth spinal nerve also gives branch to crural nerve before this union. Crural branch innervate outer muscles of thigh (Dvidyarthi, 1979). The tibialis nerve give branches to gastrocnemius, tibialis postieus and numerous muscles of the planter surface of the foot. The peroneus supplies the peroneus muscle tibialis (Jordan and Verma, 1997a) (Figure 1.3). 10<sup>th</sup> or coccygeal nerve comes out from a small hole on the side of the urostyle near its anterior end. It is a slender nerve and eventually joins the sciatic nerve. Its fine branch innervates the bladder and the cloaca. It is generally absent in the Indian frog, *Rana tigrina* (Dvidyarthi, 1979). But in other frog as in our practical animal, *Rana esculenta*, it is present (Figure 1.1). The root of the last four pair (7-10) of spinal nerves is elongated forming bundles of nerves called cauda equine, which lies inside the vertebral column among the fulum terminale.

In *Uromastix*, which is representing reptiles, nerve arising from 20<sup>th</sup> vertebrae leave the neural canal between 20<sup>th</sup> and 21<sup>st</sup> vertebrae, nerve arising from 21<sup>st</sup> vertebrae leave the neural canal between 21<sup>st</sup> and 22<sup>nd</sup> vertebrae (Figure 2.1-2.3, 2.5-2.6). These two separate nerves arising from 20<sup>th</sup> and 21<sup>st</sup> vertebrae unite to form sciatic nerve innervating inguinal, pelvic, and hind leg muscles and thus connecting the spinal cord with limb (Figure 2.1-2.3). Basically the more posterior nerve roots give rise to the obturator nerve to the ventral pelvic muscles, and the ichiadicus nerve, which runs to the muscles of the ilium and then divides to form the peroneal and sciatic nerves (Figure 2.1). The anterior two nerve roots interconnect provide major innervations (via crural, femoral, and tibial nerves) to the inguinal muscles, thigh adductors, and leg extensors (Figure 2.1-2.6). The sciatic nerve runs from the lower spine, through the pelvic area, and down through back of the leg. Sciatic nerve branches further into two main branches, tibial and peroneal nerve (Figure 2.1-2.6). One out of these branches divided into two further branches. The tibial nerve gives branches to gastrocnemius, tibialis posterior and numerous muscles of the planter surface of the foot. The peroneal nerve supplies the peroneus muscle. There are also sacral branches going to the bladder. Sacral nerves are presumed to innervate the genitalia. Caudal nerve innervate tail region of *uromastix*. Small branches from sciatic nerve also run down tail region. In Rabbit, which is a mammal, 7<sup>th</sup> lumbar nerve arising from 27<sup>th</sup> vertebrae, leave the spinal cord between 7<sup>th</sup> lumbar and 1<sup>st</sup> sacral nerve, and 1<sup>st</sup> sacral nerve arising from 28<sup>th</sup> vertebrae leave the spinal cord between 1<sup>st</sup> and 2<sup>nd</sup> sacral nerve (Figure 3.1, 3.5, 3.6). These 7<sup>th</sup> lumbar and 1<sup>st</sup> sacral nerve originating from 27<sup>th</sup> and 28<sup>th</sup> vertebrae unite to form sciatic nerve which gives out different branches further to innervate the thigh and leg region (Jordan and

Verma, 1997c) (Figure 3.1, 3.5, 3.6). This large nerve innervates the muscles found in the posterior region of the thigh and originates from the seventh lumbar and first sacral nerves (Popesco *et al.*, 1992). It passes through sciatic notch and become visible near piriform muscles. Sciatic nerve run down and gives branches to gluteal muscles. Further sciatic nerve innervating the Semitendinosus and semimembranosus; branches at knee and two main branches, tibial and peroneal nerve are formed (McLaughlin and Chiasson, 1990). The tibial nerve innervates gastrocnemius muscle, soleus, tibialis posterior, flexor digitorum longus, and flexor hallucis longus muscle (Figure 3.8, 3.3-3.5, 3.7). Branches of tibial nerve in foot are medial plantar and lateral plantar nerves. Peroneal nerve divides into superficial nerve innervating to peroneus longus and peroneus brevis muscle and deep peroneal nerve innervating tibialis anterior, extensor hallucis longus, peroneus tertius and extensor digitorum longus and brevis muscle (Figure 3.8, 3.3-3.5, 3.7). Laterally sciatic nerve gives branches to semimembranosus, medially and superficially it innervates biceps femoris (Figure 3.1, 3.3-3.7). 4<sup>th</sup> sacral nerve supplies to the skin and muscle of sacral region. (Germana *et al.*, 1992) observed that in the rabbit the myelinated fibres with the largest diameter originating from the sciatic nerve distribute mainly into the peroneal nerve. The distribution of the myelinated fibre diameters is unimodal in the sciatic nerve, but bimodal both in the peroneal and tibial nerves. The quotient axon diameter/fiber diameter (g ratio) shows a different trend between the sciatic nerve and the branches originating from it. Except for the peroneal nerve, the increase of the axon calibre corresponds to the reduction of the relative myelin sheath thickness and therefore to the reduction of internodal distance. The results show that the sciatic nerve and its terminal branches in the rabbit have morphometrical characteristics that are peculiar and differ from those of the other rodents. Fumio *et al.*, (2000) conclude that the components of sciatic nerve in Sprague-Dawley rats vary from L3 to L6; however, the major components are L4 and L5 macroscopically. This finding is in contrast to the standard textbooks of rat anatomy, which describe the sciatic nerve as having major contributions from L4, L5, and L6. In birds there are anatomical specializations in the lumbosacral vertebrae and spinal cord. Results support the assumption that the lumbosacral specializations are involved in the control of locomotion on the ground (Necker *et al.*, 2000). Janjua and Leong, (1984) revealed that the sciatic nerve (ScN) neurons are distributed to L4-L7 segments in all monkeys studied and also to the rostral part of S1 segment in some monkeys. These anatomical differences of sciatic nerve course are basically due to difference in their representing class, like amphibians, reptiles, and mammals, This variation represents that they have different mode of locomotion like in frog, jumping and leaping on land, swimming and floating in water, in uromastix, creeping and running on land and in rabbit, walking, running and leaping on land (Jordan and Verma, 1997e), because lumbosacral specializations are involved in the control of locomotion (Necker *et al.*, 2000). Sciatic nerve diameter also varies among these animals, when we compared among these animals, sciatic nerve is the thickest in rabbit. In case of frog the sciatic nerve is a large bundle of many nerve fibers. The fibers come out between vertebrae at the caudal end of the vertebral column. The nerve of the frog can be dissected from its origin at the spinal cord as 3-4 bundles of the sciatic plexus, all the way to the gastrocnemius muscle (Figure 1.3). There the nerve divides into two branches, one to each head of the muscle. As we proceed distally along the nerve, from the plexus, we find fibers leaving the main trunk and entering muscles and skin. Therefore, having fewer fibers, the distal end of the nerve is of smaller diameter than the proximal end at the plexus (Easton, 2000). In uromastix when nerve arises from 20<sup>th</sup> and 21<sup>st</sup> vertebrae, it is thicker as compared to branches going below the knee (Figure 2.1-2.4). Having fewer fibers, the distal end of the nerve is of much smaller diameter than the proximal end at the plexus when compared with frog (Figure 2.2). Whereas in rabbit sciatic nerve arises from 27<sup>th</sup> and 28<sup>th</sup> vertebrae, is the thickest nerve (Figure 3.1, 3.6). As we proceed distally along the nerve, from the plexus, we find fibers leaving the main trunk and entering muscles of hindlimb and skin. Therefore, having fewer fibers, the distal end of the nerve is of smaller diameter than the proximal end at the plexus. But branches below the knee are of greater diameter when we compared with both frog and uromastix (Figure 3.2, 3.4-3.5, 3.8). In experimental work sciatic nerve is easily isolated in frog. Because the spinal nerves are best studied in the frog and they are exposed on the dorsal wall of the body cavity, instead of being deep in the flesh as in the rat. They appear as whitish, thread-like structures that emerge from between the vertebrae and lie along the dorsal wall of the body cavity (Campbell, 1999). While in case of uromastix, very small branches going below the knee, it is very difficult to isolate sciatic nerve as a whole. And in rabbit sciatic nerve is present very deep in the flesh. Frog sciatic nerve arises from 8<sup>th</sup> and 9<sup>th</sup> spinal nerve innervating to all the muscles required for its all type of locomotion like jumping and leaping on land, swimming and floating in water. Particularly thicker tibial nerve innervating gastrocnemius muscles, help in its fast muscles activity required for its locomotion (Jordan and Verma, 1997e). In case of uromastix, sciatic nerve arises from 20<sup>th</sup> and 21<sup>st</sup> spinal nerve innervating to all the muscles required for its all type of locomotion like creeping and running on land. Particularly thinner tibial nerve innervating gastrocnemius muscles, help in its less fast muscles activity required for its locomotion. Some branches of sciatic nerve also innervate caudal region help in maintaining balance of body during its locomotion (Jordan and Verma, 1997e). Rabbit sciatic nerve arises from 27<sup>th</sup> and 28<sup>th</sup> spinal nerve innervating to all the muscles required for its all type of locomotion like running, walking, and leaping on land. Particularly thicker tibial nerve innervating gastrocnemius muscles, help in its fast muscles activity required for its locomotion. In

case of rabbit, the diameter of peroneal is also greater than in frog and uromastix. Some branches of sciatic nerve also innervate caudal region help in maintaining balance of body during its locomotion (Jordan and Verma, 1997e).



**Fig. 4. Movement of Frog, Uromastix and Rabbit**

The purpose of this study was to compare sciatic nerve anatomy, its branches to different muscles and morphometric characteristics vary in frog, uromastix and rabbits (Fig. 4a,b,c,d). We have found clear difference in the course of sciatic nerve among these three animals, it is definitely on the basis of the their branches and diameter innervating both slow and fast muscle fibre types. So we are able to conclude that the differences in the course of sciatic nerve reflect exactly the evolutionary differences reported in these animals along with the locomotion they have as per their habitat.

## References

- Akita, K. (1992). An anatomical investigation of the muscles of the pelvic outlet in iguanas (*Iguanidae Iguana iguana*) and varanus (*Varanidae Varanus (dumerillii)*) with special reference to their nerve supply. *Ann Anat.* 174 (2):119-29.
- Bergman, R.A., Afifi, A.K. and Miyauchi, R. (1988). *Compendium of human anatomical variations*, Baltimore, Urban and Schwarzenberg 146.
- Campbell. (1999). *The Nervous System*, Modified Sept 2005, 7th Ed. 1013-1014.
- Easton, D.M. (2000) *The Nerve Impulse Seen from Outside*.
- Dvidyarthi, R. (1979). *Text book of Zoology*. Edition 1979: 186-189.
- Franhenhauser, B. and Widen, L. (1965) Anode break excitation in de-sheated frog nerve. *J. physiol.* 131: 243-247.
- Fumio A., Butler, M., Blomberg, H. and Gordh, T. (2000). Variation in rat sciatic nerve anatomy: Implications for a rat model of neuropathic pain, *Journal of the Peripheral Nervous System* 5-19.
- Gerard, J. Tortora, Nicholas, P. and Anagnostakos, (1992). The spinal cord and the spinal nerves in principles of anatomy and physiology, seventh edition 377-400.
- Germana, G., Muglia, U., Santoro, M., Abbate, F., Laura, R., Gugliotta, M.A., Vita, G. and Ciriaco, E. (1992). Morphometric analysis of sciatic nerve and its main branches in the rabbit. 4 (1):11-5.
- Helen, J.H. and Montgomery, J. (1996). *Cranial and ppheripheral nerves and the muscles they innervates in muscle testing* sixth edition 410-417.
- Janjua, M.Z. and Leong, S.K. (1984). Organization of neurons forming the femoral, sciatic, common peroneal and tibial nerves in rats and monkeys, *Sep.* 24.310(2): 311-23.
- Jordan, E.L. and Verma, P.S. (1997a,b,c,d,e). *Cordate Zoology* 11<sup>th</sup> edition. S. Chand and Company Ltd. Ram Nagar, New Delhi. pp. 1092.
- Khalil, F. and Masseih, G.A. (1954). Water content of desert reptiles and mammals, *J. expt. Zool.* 125: 407-414.
- Lord, W. (1991). *Trauma and the nervous system. Essentials of neurology* 6<sup>th</sup> edition 201-214.
- Mark, M. (1990). *Lesions of ppheripheral nerves in neurology*, 3<sup>rd</sup> edition 387-438.

- McLaughlin, C.A. and Chiasson, R.B. (1990). *Laboratory Anatomy of the Rabbit*, McGraw-Hill, New York 1990.
- Necker, R., Janssen, A. and Beissenhirtz, T. (2000). Behavioral evidence of the role of lumbosacral anatomical specializations in pigeons in maintaining balance during terrestrial locomotion *J. Comp. Physiol.* 186 (4): 409-12.
- Popesko, P., Rajtova, V. and Horak, J. (1992). *A Colour Atlas of Anatomy of Small Laboratory Animals*, V1. Wolfe Publishing Ltd. London, England.
- Raymond, D. A. and Victor, M. (1993). *Diseases of the peripheral nerves. Principles of neurology fifth edition* 1117-1170.
- Rotem, A. and Moses, E. (2006). Magnetic stimulation of curved nerves. 53(3): 414-20.
- Schwemmer, U., Markus, C.K., Greim, C.A., Brederlau, J., Kredel, M. and Roewer, N. (2005). Sonographic imaging of the sciatic nerve division in the popliteal fossa. 26(6): 496-500.
- Swett J.E., Torigoe, Y., Elie, V.R., Bourassa, C.M. and Miller, P.G. (1991). Sensory neurons of the rat sciatic nerve. *Exp Neurol.* 114(1): 82-103.
- Winegrad, S. and Shanes, A.M. (1962). Calcium flux and contractility in guinea pig atria *J.Gen Physiol.* 345-372.